

Clinical Significance of Distinguishing Between Follicular Lesion and Follicular Neoplasm in Thyroid Fine-Needle Aspiration Biopsy

Michelle D. Williams, MD¹, James W. Suliburk, MD², Gregg A. Staerke, MD¹, Naifa L. Busaidy, MD³, Gary L. Clayman, MD⁴, Douglas B. Evans, MD⁵, and Nancy D. Perrier, MD⁶

¹Department of Pathology, The University of Texas M.D. Anderson Cancer Center, Houston, TX; ²The Michael E. DeBakey Department of Surgery, Baylor College of Medicine, Houston, TX; ³Department of Endocrine Neoplasia and Hormonal Disorders, The University of Texas M.D. Anderson Cancer Center, Houston, TX; ⁴Department of Head and Neck Surgery, The University of Texas M.D. Anderson Cancer Center, Houston, TX; ⁵Department of Surgery, Medical College of Wisconsin, Milwaukee, WI; ⁶Department of Surgical Oncology, The University of Texas M.D. Anderson Cancer Center, Houston, TX

ABSTRACT

Background. Subclassifying indeterminate thyroid fine-needle aspiration (FNA) biopsy findings as follicular lesion or follicular neoplasm has been suggested as useful in triaging patients to observation or surgery, respectively. However, terminology and therefore the probability of malignancy vary between pathologists and institutions. The purpose of this study was to evaluate a single institution's experience with indeterminate thyroid FNA results to determine if subclassification (neoplasm versus lesion) aids in identifying patients at higher risk for malignancy.

Methods. From 1990 to 2006, all patients with indeterminate thyroid FNA results (follicular lesion or neoplasm) at The University of Texas M.D. Anderson Cancer Center were evaluated for FNA correlation with the surgical specimen diagnosis. Patients with FNAs suspicious for papillary thyroid carcinoma or with definitive malignant disease (i.e., metastases) were excluded.

Results. Indeterminate FNA results were present in 540 patients, including 410 as follicular lesion and 130 as follicular neoplasm. Two hundred ninety-seven (55.0%) patients underwent surgical resection: 199 (48.5%) follicular lesions and 98 (75.4%) follicular neoplasms. Incidence of malignancy was higher in thyroid nodules classified as

neoplasm compared with lesion (21.4% versus 7.0%, respectively; $P = 0.0005$) and increased in follicular neoplasms with nodule size (37.5% malignant if nodule was >4 cm, $P = 0.03$).

Conclusions. Subclassification of indeterminate thyroid FNA biopsy results into neoplasm and lesion successfully defines high- and low-risk nodules, respectively. These findings support surgical resection for follicular neoplasms, selective use of surgical intervention for follicular lesions at our institution, and continued efforts to define unified terminology between institutions.

Thyroid fine-needle aspiration (FNA) biopsy is the standard diagnostic procedure used to evaluate thyroid nodules larger than 1 cm in diameter or nodules with suspicious findings on transcutaneous ultrasound. FNA biopsy can accurately separate the majority of thyroid nodules into benign or malignant processes, allowing patients to be triaged to observation or surgery.^{1,2} However, 15–30% of thyroid FNA biopsy results are classified as “indeterminate,” a group of variably defined cytologic findings which may represent the entire spectrum of thyroid biology from reactive and benign to malignant nodules. Moreover, the cytologic criteria used to evaluate indeterminate FNAs and the terminology used to classify findings based on the probability of malignancy vary between pathologists and between institutions.^{2–10} The variable terminology, uncertainty regarding the biologic nature of these thyroid nodules, and the ill-defined rate of malignancy creates uncertainty for optimal patient

management (surgical resection, observation or rebiopsy) to recommend to these patients.

In an effort to standardize terminology, which would allow better comparison of patients and outcomes across institutions, the National Cancer Institute (NCI) Thyroid FNA State of the Science Conference Committee IV has proposed six diagnostic categories based on the cytologic features of FNA specimens from thyroid tumors (Table 1).¹¹ Other systems for classification of thyroid tumors based on FNA biopsy results have been put forth by the American Thyroid Association, the American Association of Clinical Endocrinologists, and the Papanicolaou Society of Cytopathology (Table 1).¹²⁻¹⁴ Regardless of which system is used, the definitions and classifications used by pathologists, and the clinical implications of such classifications, must be consistently and accurately applied and understood to allow clinicians to optimize patient care. By standardizing the risk of malignancy associated with each cytologic diagnosis, patients can be appropriately counseled as to the need for surgical intervention.

At the University of Texas M.D. Anderson Cancer Center, a group of pathologists, all cytopathology board certified (many fellowship trained at our institution), provide the diagnostic readings of thyroid FNA biopsies from Papanicolaou and/or Diff-Quik stained direct smears, which are almost exclusively performed under ultrasound guidance. The terms used to classify indeterminate follicular thyroid FNA biopsy findings include "follicular lesions" and "follicular neoplasm," which denote different pathologic interpretations. The cytologic findings in follicular lesion raise the broad differential diagnosis from hyperplasia to follicular neoplasia; follicular adenoma is favored but follicular carcinoma cannot be completely excluded, based on the inability to assess capsular/vascular invasion in aspiration specimens. The diagnosis of follicular neoplasm implies that the pathologist's suspicion for malignancy is increased secondary to cytologic findings including nuclear atypia, pronounced microfollicular architecture, trabecular pattern, complete or near-complete loss of colloid, necrosis or mitosis, and therefore the need for surgical intervention for complete pathologic evaluation is raised. Ultimately, the clinician advises the patient to undergo surgery or continued observation (with or without repeat biopsy) based on the clinical, radiographic, and FNA risk assessment. Because the diagnostic criteria for follicular lesion and follicular neoplasm used at M.D. Anderson Cancer Center are in general consistent with those proposed by the recent NCI committee we decided to evaluate the utility of these categories in discriminating between benign and malignant thyroid nodules.⁶ Specifically, we sought to determine if our cytologic classification of thyroid nodules as lesion or neoplasm based on FNA biopsy findings resulted in different rates of

malignancy and different rates of surgical intervention. To accomplish this goal, we retrospectively reviewed records for patients at our institution who had a cytologic diagnosis of follicular lesion or follicular neoplasm based on FNA biopsy and subsequently underwent surgical resection for histologic tumor classification.

METHODS

Following approval by the institutional review board for this retrospective study, we reviewed the pathology database for all patients who underwent a thyroid FNA biopsy at M.D. Anderson Cancer Center between January 1, 1990 and December 31, 2006 and who were diagnosed as having an indeterminate thyroid nodule, using the search terms "follicular lesion" or "follicular neoplasm." The cytologic classification of follicular lesion comprises cytologic smears demonstrating increased cellularity composed of bland follicular epithelial cells arranged in a microfollicular pattern with scant colloid. The differential diagnosis of follicular lesion includes benign thyroid hyperplasia or adenoma, as well as follicular carcinoma, which requires architectural capsular invasion or lymphatic invasion for definitive diagnosis. In contrast, the term follicular neoplasm comprises cytology smears with increased cellularity composed of follicular epithelial cells with atypical features, including uniformly enlarged nuclei in a microfollicular pattern or nuclei forming trabeculae and/or the presence of mitoses or necrosis.

For purposes of this report, we used the cytologic diagnosis as it appeared in the pathology report without re-review of the pathologic slides, as this was the pathologic classification which was used to determine if surgical evaluation was warranted. Any patient with a confirmed thyroid malignancy (i.e., positive lymph node or distant metastases) at the time of FNA biopsy was excluded. Patients with an FNA biopsy result of suspicious for papillary thyroid carcinoma were also excluded as there is general consensus for thyroidectomy in these patients. Demographic information including gender and age were noted to evaluate for any differences between pathologic groups or in the determination for surgical evaluation.

All FNA biopsy cytology reports were reviewed, and the evaluating pathologist and size of the biopsied thyroid nodule were recorded. All corresponding surgical pathology reports were reviewed, for the histologic diagnosis. Thyroid nodules classified histologically (following resection) as of uncertain malignant potential were placed in the benign group for purposes of this analysis. Cases with histologic evidence of incidental papillary thyroid microcarcinoma (<1.0 cm) in nodules other than the index lesion that underwent FNA biopsy were also grouped in the benign category.

TABLE 1 Features of proposed terminology for thyroid FNA biopsy results by different committees/institutions/organizations^a

Classification	NCI thyroid consensus ¹¹	MDACC	ATA ¹³	Endocrine ¹⁴	Papanicolaou ¹⁵	Clinical triage
No. of diagnostic categories	6	6	4	4	5	
Inadequate/nondiagnostic	×	×	×	×	×	Repeat FNA
Benign	×	×	×	×	×	Observation
Indeterminate			×	(subdivided below into)		Clinical/ radiographic correlation
Follicular lesion of undetermined significance ^b		Follicular lesion			Atypical cells present/cellular follicular lesion	Clinical/radiographic correlation
Follicular neoplasm		Follicular neoplasm	Suspicious for neoplasia	Follicular neoplasia		Surgery
			Suspicious for carcinoma			Surgery
Suspicious for malignancy	×	×			×	Surgery
Malignant	×	×	×	Malignant/suspicious	×	Surgery

Non-shaded cells are categories generally agreed upon for classification and clinical triage; shaded rows are indeterminate categories with variable terminology between groups with uncertainty for clinical triage

FNA fine-needle aspiration, NCI National Cancer Institute, MDACC M.D. Anderson Cancer Center, ATA American Thyroid Association, Endocrine American Association of Clinical Endocrinologists, Papanicolaou Papanicolaou Society of Cytopathology

^a Similar categories between classification schemas are approximate

^b Synonymous terms with equivalent meaning per NCI discussions. Atypia of undetermined significance cannot rule out neoplasm, atypical follicular lesion or cellular follicular lesion

Fisher’s exact test was used to compare differences between the follicular lesion and neoplasm groups with regard to the incidence of surgery, rate of malignancy, and pathologic and demographic parameters. Chi-square analysis was used to compare the size of nodules between groups. *P* values of ≤ 0.05 were considered significant. Evaluation of each pathologist’s reporting pattern and correlation between the cytopathology diagnosis and the histologic diagnosis from biopsy of surgical specimens were also compared to determine the utility of the pathologic classification follicular neoplasm.

RESULTS

During the 17-year period of interest, 540 thyroid nodules in 540 patients were classified as indeterminate for malignancy on FNA biopsy, that is, 410 (75.9%) lesions were categorized as follicular lesions and 130 (24.1%) as follicular neoplasms (Fig. 1). Surgical resection and histologic evaluation of the index nodule was performed in 297 (55.0%) of the initial 540 patients: 199 (48.5%) with follicular lesions and 98 (75.4%) with follicular neoplasms (*P* = 0.007) (Table 2). Histologic evidence of differentiated thyroid cancer was found in 35 (11.8%) of the 297 thyroid specimens: 14 (7.0%) of 199 follicular lesions and 21 (21.4%) of 98 follicular neoplasms (*P* = 0.0005) (Table 2). The 35 carcinomas included 27 follicular carcinomas (18 with a cytologic diagnosis of neoplasm; 9 diagnosed as lesion) and 8 papillary thyroid carcinomas (3 classified as neoplasm; 5 classified as lesion) (Fig. 1). Follicular nodules of uncertain malignant potential were also identified in six cases (three as neoplasm; three as lesion). Over time, the rate of follicular carcinoma by year was constant (most often two per year throughout the study). Similarly, the rate of papillary thyroid carcinoma averaged 0–1 per year.

TABLE 2 Classification of thyroid fine-needle aspiration (FNA) biopsies as lesion versus neoplasm with incidence of surgery and surgical pathologic diagnosis

Triaged	Thyroid FNA biopsy diagnosis		<i>P</i> value
	Lesion (<i>N</i> = 410)	Neoplasm (<i>N</i> = 130)	
Surgery ^a	199 (48.5%)	98 (75.4%)	<i>P</i> = 0.007
No surgery ^b	211 (51.5%)	32 (24.6%)	
<i>Surgical specimen diagnosis</i>			
Benign ^c	185 (93.0%)	77 (78.6%)	<i>P</i> = 0.0005
Malignant ^d	14 (7.0%)	21 (21.4%)	

^a Surgical intervention (hemi- or total thyroidectomy) performed at our institution

^b No surgical intervention at our institution by the time of this study

^c Benign includes adenoma, hyperplasia, and lesions of uncertain malignant potential

^d Malignant includes malignancy in nodule that had undergone FNA biopsy; diagnoses included follicular and papillary carcinomas (incidental microcarcinomas were excluded)

Patient sex and age, and nodule size were comparable between groups of patients diagnosed with follicular lesion and follicular neoplasm; this was true in the subgroup of patients who underwent surgical resection as well (Table 3). In the group of patients with a cytopathologic diagnosis of follicular neoplasm who underwent surgery, malignant thyroid nodules were more likely to be larger than benign nodules (mean, 3.4 cm versus 2.6 cm; *P* = 0.03). The incidence of malignancy in follicular neoplasms increased with nodule size, from 11.8% for nodules 1.1–2.0 cm to 27.6% for nodules 2.1–3.0 cm, 25.0% for nodules 3.1–4.0 cm, and 37.5% for nodules >4.0 cm (Table 4). In the follicular lesion group who underwent surgery, benign lesions were larger than malignant ones, with mean diameters of 2.8 and 2.3 cm, respectively, although the difference was not significant (*P* = 0.15). Other characteristics, including patient age and sex, were similar between subgroups of patients with benign and malignant nodules in both the follicular lesion and follicular neoplasm groups.

During the study period, 22 pathologists rendered the cytologic diagnoses in these 540 patients. The mean number of reports completed by each pathologist was 24.5 (median 20, range 1–95). Fourteen of the 22 pathologists gave a diagnosis of indeterminate thyroid nodule from an FNA biopsy ten or more times (that is, they had a high volume of such diagnoses). These 22 pathologists completed an average of 36.6 reports each, which accounted for 513 (95.0%) of the indeterminate diagnoses in this study. The other eight pathologists completed the remaining 27 (5.0%) reports, averaging 3.4 reports each (low volume). The frequency of using the terms follicular lesion and follicular neoplasm varied between pathologists. For the 16

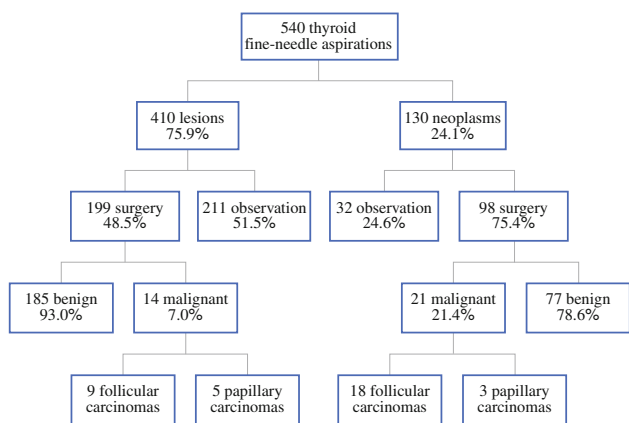


FIG. 1 Flow chart showing classification of thyroid fine-needle aspirations (FNA) biopsies, clinical triage, and histologic diagnosis on surgical specimens

TABLE 3 Clinical and pathologic features of cases with indeterminate thyroid FNA biopsy findings

Feature	All cases		Cases proceeding to surgical resection		P value
	Lesion (N = 410)	Neoplasm (N = 130)	Lesion (N = 199)	Neoplasm (N = 98)	
<i>Sex</i>					
Male	127 (31.0%)	48 (36.9%)	52 (26.1%)	32 (32.6%)	All: lesion vs. neoplasm $P = 0.2$
Female	283 (69.0%)	82 (63.1%)	147 (73.9%)	66 (67.4%)	Surgery: lesion vs. neoplasm $P = 0.3$ Lesion: all vs. surgery $P = 0.3$ Neoplasm: all vs. surgery $P = 0.6$
<i>Age (years)</i>					
<45	127 (31.0%)	46 (35.4%)	74 (37.1%)	39 (39.8%)	All: lesion vs. neoplasm $P = 0.4$
≥45	283 (69.0%)	84 (64.6%)	125 (62.9%)	59 (60.2%)	Surgery: lesion vs. neoplasm $P = 0.7$
Range (mean)	14–88 (52.2)	15–86 (50.9)	15–80 (50.5)	16–86 (49.5)	Lesion: all vs. surgery $P = 0.1$ Neoplasm: all vs. surgery $P = 0.6$
<i>Nodule size (cm)</i>					
Mean	2.6	2.7	2.8	2.8	All: lesion vs. neoplasm $P = 0.3$
Median	2.2	2.5	2.6	2.5	Surgery: lesion vs. neoplasm $P = 0.8$
Range	0.3–8.0	0.5–10.7	0.3–8.0	0.5–10.7	Lesion: all vs. surgery $P = 0.08$ Neoplasm: all vs. surgery $P = 0.9$
<i>Histologically malignant nodules</i>			14 (7.0%)	21 (21.4%)	
Follicular carcinoma			9	18	
Papillary carcinoma			5	3	
<i>Histologically benign nodules</i>			185 (93.0%)	77 (78.6%)	
UMP			3	3	
Adenoma			114	61	
Adenomatous/goiter			43	10	
Other/Hashimoto's			25	3	
<i>Background thyroid</i>					
Microcarcinomas ^a			20	3	

FNA fine-needle aspiration, UMP uncertain malignant potential

^a Papillary thyroid microcarcinoma <1.0 cm

TABLE 4 Frequency of malignancy based on fine-needle aspiration (FNA) biopsy classification and nodule size^a

	Size (cm)	No. malignant	Total no. to surgical resection	Total no. FNAs	% Malignant	% to surgical resection
<i>Neoplasms</i>						
	≤1.0	0	7	13	0	53.8
	1.1–2.0	4	34	44	11.8	77.3
	2.1–3.0	8	29	36	27.6	80.6
	3.1–4.0	3	12	18	25.0	66.7
	>4.0	6	16	19	37.5	84.2
	Total	21	98	130	21.4	75.4
<i>Lesions</i>						
	≤1.0	1	17	51	5.9	33.3
	1.1–2.0	6	59	143	10.2	41.3
	2.1–3.0	3	54	95	5.6	56.8
	3.1–4.0	4	34	59	11.8	57.6
	>4.0	0	35	60	0	58.3
	Total	14	199	408 ^b	7.0	48.8

^a P values by chi-square for ≤2.0, 2.1–4.0, and >4.0 groupings. Lesions: benign vs. malignant, $P = 0.15$; neoplasms: benign vs. malignant, $P = 0.03$

^b Two follicular lesions sizes were not characterized at time of FNA

pathologists who used both terms, follicular lesion was used an average of 3.2 times to every 1 time follicular neoplasm was issued in a report, ranging from 1.3 to 10.3 follicular lesion interpretations to every 1 follicular neoplasm report. The term follicular neoplasm was not used in any reports by 5 of the 22 pathologists (one high-volume reporter and four low-volume reporters); follicular lesion was not used in any reports from one pathologist (a low-volume reporter).

Of the 14 pathologists who rendered ten or more indeterminate diagnoses from FNA biopsies (that is, high-volume reporters) the rate of malignancy found in the surgical specimens (lesions and neoplasms combined) varied from 0% to 25.7% (mean 10.8%) malignant cases per pathologist; two had no malignancies in the resection specimens (Fig. 2). The rate of malignancy for the follicular lesions was 0–20% (mean 6.1%) per pathologist and for follicular neoplasms was 0–66.7% (mean 20.2%) per pathologist.

Of the eight low-volume pathologists, six had no cancers in the final histology reports. The remaining two low-volume pathologists used only the term follicular lesion; three of the four patients underwent surgery, and the nodules were histologically determined to be malignant. Excluding the 27 biopsy results interpreted by the eight low-volume pathologists, histologic evidence of differentiated thyroid cancer was found in 32 (11.4%) of the 280 thyroid specimens: 11 (5.8%) of 189 follicular lesions and 21 (23.1%) of 91 follicular neoplasms ($P = 0.0001$).

DISCUSSION

At our institution, a thyroid FNA biopsy-based diagnosis of follicular neoplasm is more likely than a diagnosis of follicular lesion to be followed by a recommendation for surgery (75% of neoplasms versus 49% of lesions underwent surgery; $P = 0.007$), and the histologic diagnosis of thyroid malignancy following surgery is three times more common in patients with follicular neoplasms than in those

with follicular lesions (21.4% versus 7.0%; $P = 0.0005$). Additionally, since malignancy increased to nearly 40% in follicular neoplasms >4 cm, consideration for a total thyroidectomy in this select group of patients may be advisable. Thus, our findings support the recent NCI thyroid conference’s proposed classification system (Table 5).

The data reported herein are based on the development of clearly defined definitions for the terms follicular lesion and follicular neoplasm. Although similarities exist in the cytologic features of benign and malignant indeterminate thyroid nodules, our findings suggest that recognition of infrequent, subtle changes in cytology can successfully separate nodules into groups of those with increased risk (neoplasm) and decreased risk (lesion) for malignancy. The cytologic diagnosis of follicular neoplasm thus alerts the clinician to a subgroup of patients who appear to have a higher risk for harboring a thyroid cancer. A similar subgroup with increased incidence of malignancy was noted by Goldstein et al., who used the term “neoplasm with atypia.”¹⁵ Yang et al. observed higher rates of malignancy in both of their indeterminate categories: “atypical cellular lesion” (19% malignant) and “follicular neoplasm” (32% malignant).¹ However, it is not certain that these categories are exactly synonymous with ours, as they noted 2.5 times more papillary thyroid carcinomas than follicular

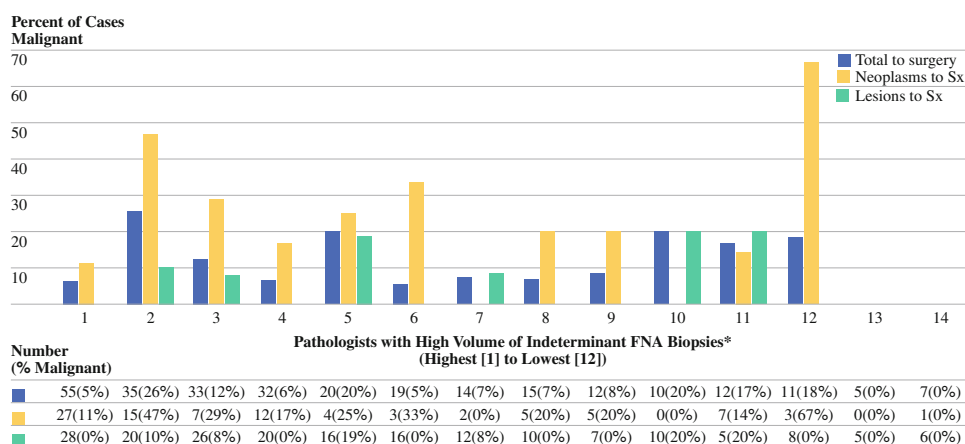
TABLE 5 Risk of malignancy in thyroid nodules with indeterminate FNA biopsy results

Thyroid FNA indeterminate classification	NCI literature summation risk of malignancy	MDACC 1990–2006
Follicular lesion/atypia of undetermined significance ^a	5–10%	7.0%
Follicular neoplasm	20–30%	21.4%

FNA fine-needle aspiration, NCI National Cancer Institute, MDACC M.D. Anderson Cancer Center

^a Synonymous terms with equivalent meaning per NCI discussions¹²

FIG. 2 Frequency of malignancy in surgical specimens for thyroid fine-needle aspiration (FNA) biopsy results classified as lesion or neoplasm by pathologist. *Pathologists evaluating at least ten thyroid FNAs with a classification as indeterminate (follicular lesion or neoplasm) during the study period



carcinomas in their follicular neoplasm group versus 0.16 times more in our study.

Variability in reporting thyroid FNA biopsy terminology within an institution and between pathologists may exist secondary to changes in personnel, preferences in terminology based on training, differences in personal philosophy, and variability in experience.^{16,17} In the case of thyroid FNA biopsies, this variability may lead to poor communication with clinicians as to the meaning of the classification provided, limiting the role of the pathologist in risk assessment for indeterminate follicular thyroid nodules.³ Additionally, the reproducibility of such classifications between pathologists may limit the utility.¹⁸ Our findings suggest that cytopathologists with higher thyroid FNA biopsy case volumes more accurately divide indeterminate follicular nodules into the lesion and neoplasm classifications, as evidenced by an improved correlation with postsurgical histology, which is also supported by others.^{2,7} Regular consensus conferences and meetings between pathologists, radiologists, and clinicians within single institutions and in the form of national and international consensus conferences will maximize the clinical utility of such nomenclature. Indeed, such interaction is the cornerstone of multidisciplinary care.¹⁹

This study supports surgical evaluation of nodules with cytomorphic features consistent with follicular neoplasm. However, clinical management of thyroid nodules classified as follicular lesions remains challenging, requiring incorporation of other factors. Follicular lesion remains a group with overlapping cytologic features which includes adenomatous nodules, adenomas and possibly follicular carcinomas.²⁰ Thus the pathologic diagnosis of follicular lesion by FNA biopsy must be combined with the clinical factors and radiographic findings to determine a patient's management. Because the use of the term follicular lesion as defined in this report did define a subgroup of patients with indeterminate FNA biopsy results who had a lower rate of malignancy (7% in those undergoing surgery), observation is a reasonable course of action in carefully selected patients, with continuing serial follow-up remaining very important. For indeterminate follicular lesions with worrisome ultrasonographic features of malignancy (increase vascularity or calcification) patients would be counseled regarding surgical resection for complete evaluation. In patients without worrisome ultrasonographic findings (i.e., adenomatous goiters), observation with repeat ultrasound in 6 months to 1 year may be considered, with repeat biopsy at that time if new ultrasonographic findings are worrisome and/or the nodule is growing (increase in size by $\geq 20\%$). Similarly small nodules (< 1 cm) may be monitored for change in size over time. It is possible that repeat biopsy in a follicular lesion would provide additional cytologic features to allow for a more definitive classification (i.e., the presence of more colloid

allowing classification as a benign nodule or increased microfollicular cellularity changing classification to a neoplasm) which would aid further clinical management. In patients with such cytology findings, other risk factors such as age, sex, and nodule size may aid in the triage process, however these factors were not statistically different in our study. Size may not have correlated in the follicular lesion secondary to FNA in solid nodules present within goiters (large and benign) and ultrasound targeting suspicious smaller lesions such as those with increased vascularity (small follicular variant of papillary thyroid carcinomas; five of the nine malignancies in the follicular lesion group). Other investigators have also emphasized the integration of all clinical and radiologic data into clinical decision-making for patients with indeterminate FNA biopsy results.^{20–23}

Our findings support the national trend among cytopathologists who have considerable exposure to indeterminate follicular lesions, i.e., that cytomorphic factors do in fact exist to successfully classify thyroid nodules into the more worrisome category, follicular neoplasm, for which the rate of malignancy exceeds that which would be accounted for by chance. Other factors that may account for our findings include our cohesive group of pathologists, some of whom were trained by each other, and our institution's collaborative approach to patient care, especially for difficult-to-interpret FNA specimens. The ultimate challenge will be to reproduce such results across institutions. Importantly, our findings provide additional support for the use of the recently proposed NCI Thyroid State of the Science Committee IV recommendation of a six-tiered system, with indeterminate follicular nodules stratified as follicular lesion, indicating a lower rate of malignancy (5–10%), and follicular neoplasm, indicating a 3–6 times higher rate of malignancy (20–30%).¹¹ The unification of cytology terminology is a necessary first step in risk stratification and will allow clinicians the option of considering observation, rather than thyroidectomy, in selected patients with indeterminate thyroid FNA biopsy results. The degree to which clinicians accept these data will likely be proportionate to their multidisciplinary interdepartmental interactions within their institutions; our findings offer additional support for a multidisciplinary approach to the care of cancer patients.

REFERENCES

1. Yang J, Schnadig V, Logrono R, Wasserman PG. Fine-needle aspiration of thyroid nodules: a study of 4703 patients with histologic and clinical correlations. *Cancer*. 2007;111(5):306–15.
2. Selabas GM, Staerke GA, Shapiro SE, Fornage BD, Sherman SI, Vassilopoulos-Sellin R, et al. Fine-needle aspiration of the thyroid and correlation with histopathology in a contemporary series of 240 patients. *Am J Surg*. 2003;186(6):702–9 (discussion 709–10).
3. Redman R, Yoder BJ, Massoll NA. Perceptions of diagnostic terminology and cytopathologic reporting of fine-needle

- aspiration biopsies of thyroid nodules: a survey of clinicians and pathologists. *Thyroid*. 2006;16(10):1003–8.
4. Wu HH, Jones JN, Osman J. Fine-needle aspiration cytology of the thyroid: ten years experience in a community teaching hospital. *Diagn Cytopathol*. 2006;34(2):93–6.
 5. Yoder BJ, Redman R, Massoll NA. Validation of a five-tier cytodiagnostic system for thyroid fine needle aspiration biopsies using cytohistologic correlation. *Thyroid*. 2006;16(8):781–6.
 6. Raber W, Kaserer K, Niederle B, Vierhapper H. Risk factors for malignancy of thyroid nodules initially identified as follicular neoplasia by fine-needle aspiration: results of a prospective study of one hundred twenty patients. *Thyroid*. 2000;10(8):709–12.
 7. Tan YY, Kebebew E, Reiff E, Caron NR, Oglivie JB, Duh QY, et al. Does routine consultation of thyroid fine-needle aspiration cytology change surgical management? *J Am Coll Surg*. 2007;205(1):8–12.
 8. Baloch ZW, Livolsi VA. Follicular-patterned lesions of the thyroid: the bane of the pathologist. *Am J Clin Pathol*. 2002;117(1):143–50.
 9. Deveci MS, Deveci G, LiVolsi VA, Baloch ZW. Fine-needle aspiration of follicular lesions of the thyroid. Diagnosis and follow-Up. *Cytojournal*. 2006;3:9.
 10. El Hag IA, Kollur SM. Benign follicular thyroid lesions versus follicular variant of papillary carcinoma: differentiation by architectural pattern. *Cytopathology*. 2004;15(4):200–5.
 11. Baloch ZW, LiVolsi VA, Asa SL, Rosai J, Merino MJ, Randolph G, et al. Diagnostic terminology and morphologic criteria for cytologic diagnosis of thyroid lesions: a synopsis of the National Cancer Institute Thyroid Fine-Needle Aspiration State of the Science Conference. *Diagn Cytopathol*. 2008;36(6):425–37.
 12. Cooper DS, Doherty GM, Haugen BR, Kloos RT, Lee SL, Mandel SJ, et al. Management guidelines for patients with thyroid nodules and differentiated thyroid cancer. *Thyroid*. 2006;16(2):109–42.
 13. American Association of Clinical Endocrinologists and Associazione Medici Endocrinologi medical guidelines for clinical practice for the diagnosis and management of thyroid nodules. *Endocr Pract*. 2006;12(1):63–102.
 14. Guidelines of the Papanicolaou Society of Cytopathology for the examination of fine-needle aspiration specimens from thyroid nodules. The Papanicolaou Society of Cytopathology Task Force on Standards of Practice. *Diagn Cytopathol*. 1996;15(1):84–9.
 15. Goldstein RE, Netterville JL, Burkey B, Johnson JE. Implications of follicular neoplasms, atypia, and lesions suspicious for malignancy diagnosed by fine-needle aspiration of thyroid nodules. *Ann Surg*. 2002;235(5):656–62 (discussion 662–4).
 16. Sidawy MK, Del Vecchio DM, Knoll SM. Fine-needle aspiration of thyroid nodules: correlation between cytology and histology and evaluation of discrepant cases. *Cancer*. 1997;81(4):253–9.
 17. Bakhos R, Selvaggi SM, DeJong S, Gordon DL, Pitale SU, Herrmann M, et al. Fine-needle aspiration of the thyroid: rate and causes of cytohistopathologic discordance. *Diagn Cytopathol*. 2000;23(4):233–7.
 18. Clary KM, Condell JL, Liu Y, Johnson DR, Grzybicki DM, Raab SS. Interobserver variability in the fine needle aspiration biopsy diagnosis of follicular lesions of the thyroid gland. *Acta Cytol*. 2005;49(4):378–82.
 19. Evans DB, Crane CH, Charnsangavej C, Wolff RA. The added value of multidisciplinary care for patients with pancreatic cancer. *Ann Surg Oncol*. 2008;15(8):2078–80.
 20. Baloch ZW, Fleisher S, LiVolsi VA, Gupta PK. Diagnosis of “follicular neoplasm”: a gray zone in thyroid fine-needle aspiration cytology. *Diagn Cytopathol*. 2002;26(1):41–4.
 21. Tyler DS, Winchester DJ, Caraway NP, Hickey RC, Evans DB. Indeterminate fine-needle aspiration biopsy of the thyroid: identification of subgroups at high risk for invasive carcinoma. *Surgery*. 1994;116(6):1054–60.
 22. Tuttle RM, Lemar H, Burch HB. Clinical features associated with an increased risk of thyroid malignancy in patients with follicular neoplasia by fine-needle aspiration. *Thyroid*. 1998;8(5):377–83.
 23. Zacks JF, de las Morenas A, Beazley RM, O’Brien MJ. Fine-needle aspiration cytology diagnosis of colloid nodule versus follicular variant of papillary carcinoma of the thyroid. *Diagn Cytopathol*. 1998;18(2):87–90.